Original Article

Effect of salvianolic acid B on new bone formation in the orthopedically expanded suture: *A histological and immunohistochemical study*

Emre Kayalar[a]; Gul Tas Deynek[b]; Olgu Enis Tok[c]; Sevim Kucuk[d]

ABSTRACT

Objectives: To determine the effects of Salvianolic acid B (Sal B) on new bone formation in the orthopedically expanded premaxillary sutures in rats.

Materials and Methods: The sample consisting of Sprague Dawley rats (male, n = 14) was split in half by random selection: the experiment group (Sal B) and the control group. The premaxillary suture of each rat was expanded by bonding an open-loop spring to two maxillary incisors, each end to one tooth. A 5-day expansion period followed by a 12-day retention period was conducted. The 17-day intraperitoneal administration of Sal B was performed daily for the experiment group at a dose of 40 mg/kilo. The trial was completed after sacrificing the rats and dissection of the premaxillae for histological analysis. The amount of new bone, quantity of capillaries and intensity of inflammatory cells were histomorphometrically determined while the quantities of osteoblasts and osteoclasts were determined immunohistochemically.

Results: The Sal B group was significantly different from the control group and had greater quantities of new bone, capillaries, inflammatory cells, osteoblasts, and osteoclasts.

Conclusions: Salvianolic acid B displays a positive effect during premaxillary expansion with a greater number of capillaries potentially in association with higher bone formation and improved angiogenesis in rats. (*Angle Orthod.* 2021;91:248–254.)

KEY WORDS: Salvianolic acid B; Bone formation; Rapid maxillary expansion

INTRODUCTION

A typical procedure for transverse correction of dentofacial deformity is rapid maxillary expansion (RME). In this treatment protocol, the mid-palatal suture is opened to expand the maxilla. To identify growth stimulation, it is necessary to consider the quantity of osteoblasts and osteoid formed in the suture for a stabile transverse relationship.[1] Sutural bone remodeling occurs in the retention phase. However, it is inevitable that relapse occurs after RME.[2]

There are different risk factors reported to be the cause of relapse after RME. These include the device type, retention time, contraction of scar tissue, palatal mucosa tension, and the cumulative stresses from the articulations of the craniofacial complex.[3] Quick and acceptable bone formation within the intermaxillary suture is required to control for relapse in the early post-expansion period.[4]

More rapid formation of new bone in the expanded mid-palatal suture may be useful to shorten the retention period and there is also evidence that this may inhibit relapse of the skeletal transverse expansion. Purposefully, practitioners have worked on the acceleration of new bone formation using different

[a] Assistant Professor, Department of Orthodontics, Faculty of Dentistry, Istanbul Aydin University, Istanbul, Turkey; and Visiting Researcher, Discipline of Orthodontics and Paediatric Dentistry, School of Dentistry, The University of Sydney, Sydney Dental Hospital, Surry Hills, Australia.

[b] Private Practice, Istanbul, Turkey.

[c] Research Assistant, Department of Histology and Embryology, Faculty of Medicine, Regenerative and Restorative Medicine Research Center (REMER), Istanbul Medipol University, Istanbul, Turkey.

[d] Associate Professor, Department of Pharmaceutical Botany, Faculty of Pharmacy, Anadolu University, Eskisehir, Turkey.

Corresponding author: Dr Emre Kayalar, Assistant Professor, Department of Orthodontics, Faculty of Dentistry, Istanbul Aydin University, Florya, 34295, Istanbul, Turkey
(e-mail: emrekayalar@aydin.edu.tr)

Accepted: September 2020. Submitted: April 2020.
Published Online: November 25, 2020

© 2021 by The EH Angle Education and Research Foundation, Inc.

Downloaded from http://meridian.allenpress.com/angle-orthodontist/article-pdf/91/2/248/2792805/i0003-3219-91-2-248.pdf by Anadolu University user on 15 December 2022



Figure 1. The expansion spring.

methods such as laser stimulation[5] and the use of agents including transforming growth factor,[6] bisphosphonates,[7] antioxidants,[8] and lactoferrin.[9] More recently, researchers have studied antioxidants more closely due to their stimulatory effect on bone metabolism via osteoblastic stimulation.[7,10–12]

Salviae miltiorrhizae (danshen) is a plant belonging to the grass species, Labiatae Lagurus, which produces a new and special phenolic acid that is a water-soluble called salvianolic acid B (Sal B).[13–16] This has been historically used as an herbal remedy in traditional Chinese medicine to protect people from some diseases of the heart,[17] brain,[18] kidneys,[19] and lungs,[20] as well as cancers.[21] It has been reported that Danshen may also assist in healing of fractures by hastening bone remodeling. Trials conducted using prednisone-treated rats showed that Sal B can also prevent bone loss.[22] In another study, Sal B was shown to also enhance bone formation.[15,23] Despite previous studies highlighting the healing effect of Sal B on bony fractures, its effects on RME is lacking. Therefore, this study was designed to determine whether Sal B may lead to new bone formation in the orthopedically expanded sutures in rats.

MATERIALS AND METHODS

Animals

Animal ethics approval was obtained from the Bezmialem Foundation University (Istanbul, Turkey) Institutional Review Board and Animal Use Committee (protocol no: 2016/110) with principles followed in accordance with the Basel Declaration, 2010. In this study, male Sprague Dawley rats aged 12 weeks old and weighing 200 g $\pm$ 50 g were used. The rats were housed individually in the same room to ensure they were exposed to the same conditions: 25°C, 1 atmospheric pressure and with a 12-hour light and dark cycle. All animals were provided with free access to a standard pelleted diet and tap water.

Groups

A power analysis was conducted via the G*Power software, version 3.0.10 (Franz Faul, University of Kiel, Germany). Based on a 1:1 ratio between the groups, a sample size of 14 animals yielded more than 80% power (12 animals provided more than 75%) to detect statistical variations with a 0.40 effect size at a 95% significance level ($P < .05$). The 14 rats were randomly divided into two groups, half in the experimental Sal B group ($n = 7$) and half in the control group ($n = 7$).

Expansion

A spring made of 0.014-inch stainless steel wire was used to expand the premaxillary suture of each rat (Figure 1). Under general anesthesia, the spring was ligated to small grooves prepared close to the gingival margins of the upper incisors and fixed with flowable composite resin (Filtek, 3M ESPE, St Paul, MN) (Figure 2). The rats were anesthetized with intraperitoneal administration of xylazine (3 mg/kg; Rompun,

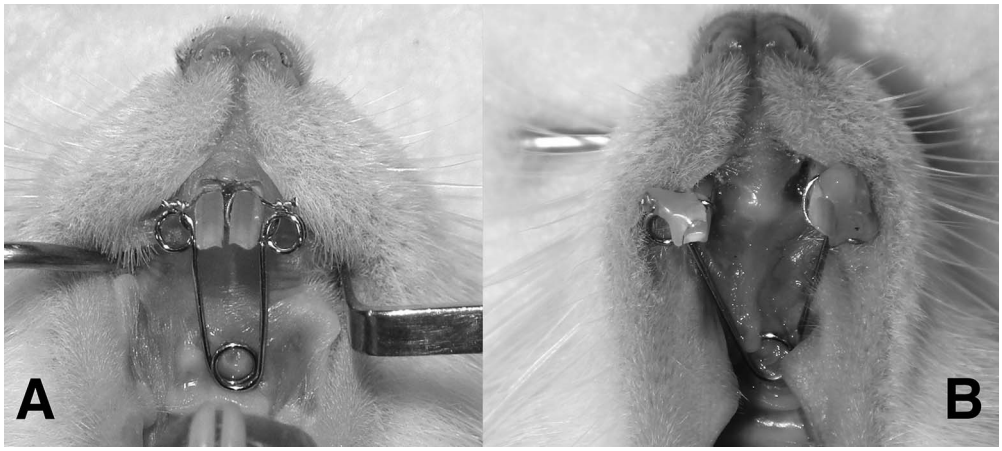

Figure 2. (A) The spring fixed to the teeth at the beginning of expansion; (B) Appliance after expansion.

Downloaded from http://meridian.allenpress.com/angle-orthodontist/article-pdf/91/2/248/2792805/i0003-3219-91-2-248.pdf by Anadolu University user on 15 December 2022

Bayer, Istanbul, Turkey) and ketamine (90 mg/kg; Ketasol, Wels, Austria).

The activated springs delivered a force of 70 g without reactivation within the 5-day expansion period, followed by a 12-day retention phase. The achievement of premaxillary expansion was confirmed by measuring the gap between the maxillary incisors with a digital caliper.[10] The expansion spring was kept in place passively on the teeth during the retention period.

Treatment Protocol

Sal B (purity $\geq$ 98%, Sigma-Aldrich, St. Louis, MO) was dissolved in isotonic sodium chloride (10 mL) and then administered intraperitoneally in the experimental group with a daily dose of 40 mg/kilo per day for 17 days throughout the expansion and retention phases.[15] The control group only received expansion and retention treatments. The experiment was completed by decapitation of rats in all groups under general anesthesia.

Histological Analysis

The premaxillae containing the mid-palatal suture of the sacrificed rats were dissected out and fixed in 10% neutral buffered formalin for 72 hours and then rinsed with 14% ethylenediaminetetraacetic acid for 4 weeks. The decalcified samples were then gradually dehydrated by increasing concentrations of ethanol series before being cleared by xylene. The samples were embedded in paraffin and sectioned into 5-μm-thick tissue sections. After staining with hematoxylin and eosin (H&E), the paraffin slides were histomorphometrically analyzed with a photomicroscope (Nikon, Eclipse i5, Tokyo, Japan). The percentage of new bone formation, as well as the number of capillaries, was measured with an image analysis system (NIS Elements Version 4.0, Nikon Instruments). Intensity of inflammatory cells was scored semi-quantitatively and graded from 0 to 3; where 0 indicated no inflammation, 1 as mild, 2 as moderate, and 3 as severe inflammation.

Immunohistochemistry

Overnight incubation of the sections cut out of paraffin blocks was performed at 37°C. These were deparaffinized with xylene and rehydrated in decreasing concentrations of ethanol, followed by incubation in methanol with 3% hydrogen peroxide for 10 minutes so that endogenous enzyme blockage would be prevented by rinsing with tap and distilled water. Afterward, antigen retrieval was achieved by microwaving the samples for 20 minutes at 200 W in a citrate buffer (6.1 pH). The slides were rinsed with phosphate buffered saline (PBS) prior to a 10-minute incubation in the blocking solution. These rinsed slides were then incubated at 4°C overnight with a mouse anti-osteocalcin primary antibody (1: 100, Abcam, Cat: ab13418) as an osteoblast marker and a rabbit-anti-cathepsin K primary antibody (1: 100, Abcam, Cat: ab19027) as an osteoclast marker. The secondary antibodies were stained using the Histostain-Plus 3rd Gen IHC Detection Kit (Cat: 85-9073, Invitrogen, Carlsbad, CA) as per the manufacturer's protocol. Two successive incubation procedures were completed for the washed sections: the first including 10 minutes in streptavidin-peroxidase at room temperature, and the second for 5 minutes in 3,3′-diaminobenzidine (DAB). At the end of the process, Mayer's hematoxylin was used to counterstain the slides before being covered with the mounting medium. Positively stained cells (osteoblasts or osteoclasts) were then counted in three different representative magnification fields.

Statistical Analysis

The obtained data were statistically analyzed using GraphPad Prism 6.0 (GraphPad Software, Inc. La Jolla, CA). Student's *t*-test was conducted as a parametric analysis and Mann-Whitney *U*-test was used as a non-parametric analysis. All data were expressed as mean $\pm$ standard error. The significance value was defined as 0.05 at most (*$P < .05$, ** $P < .01$, *** $P < .001$, **** $P < .0001$).

RESULTS

In this study, the RME technique was effective in expanding all interpremaxillary sutures in rats. Expansion of the mid-palatal suture was well-tolerated by the sample and no adverse consequences including weight loss, inflammation, or mucosal trauma occurred.

Photomicrographic display of a section in the expansion area of the control group is presented in Figure 3 and the section of the Sal B group in Figure 4. Images of immunohistochemistry of Osteocalcin as an osteoblast marker in the expansion area in the control (A) and Sal B groups (B) are presented in Figure 5, and images of Cathepsin K as an osteoclast marker are shown in Figure 6.

The histomorphometric analysis showed that the Sal B group had a significantly wider area of new bone ($P = .001$), a greater quantity of capillaries ($P < .01$) and a higher intensity of inflammatory cells ($P < .01$) than the control group (Table 1). Additionally, the experimental group had a significantly greater number of osteoblasts

Downloaded from http://meridian.allenpress.com/angle-orthodontist/article-pdf/91/2/248/2792805/i0003-3219-91-2-248.pdf by Anadolu University user on 15 December 2022

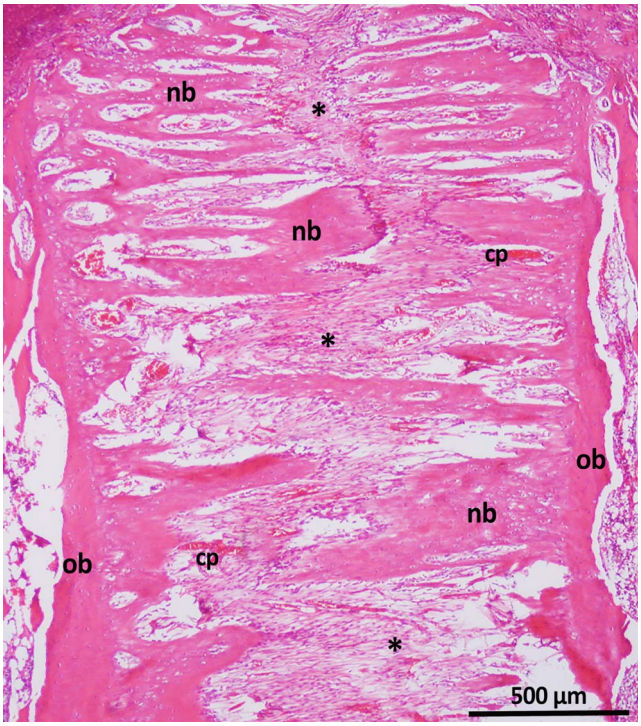

Figure 3. Photomicrographic display of a section in the expansion area of the control group. Bone trabeculae are abundantly formed and the greater amount of connective tissues indicates the initiation of bone formation. cp, capillary; nb indicates new bone; ob, old bone; *, connective tissue. Bar: 500 µm.

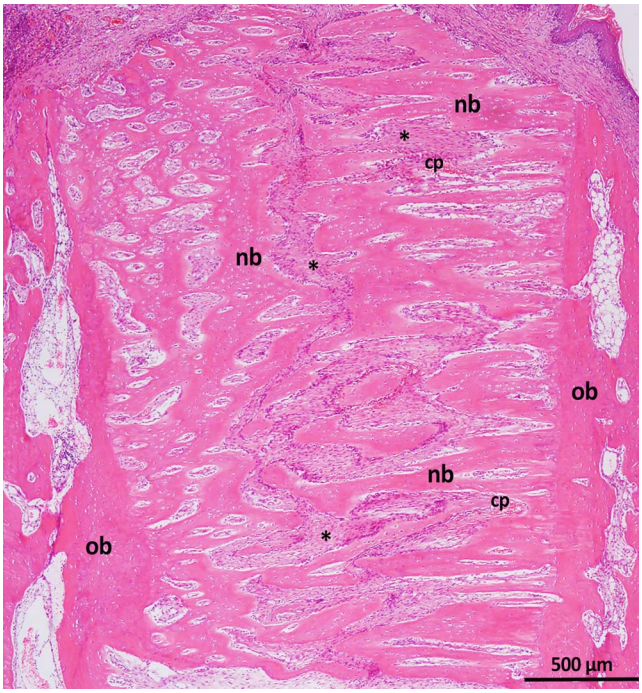

Figure 4. Photomicrographic display of a section in the expansion area of the Sal B group. The new bone trabeculae masses are extensive and new bone may be seen attached to old bone at the expansion site. cp indicates capillary; nb, new bone; ob, old bone; *, connective tissue. Bar: 500 µm.

($P < .001$) and osteoclasts ($P < .001$), compared to the control group (Table 2).

DISCUSSION

The study showed that Sal B significantly induced new bone formation in the orthopedically expanded premaxillary suture in rats when used over a period of 17 days (expansion and retention) at a dosage of 40 mg/kg/day. Based on histomorphometric analysis, new bone formed with greater osteoblasts and even greater osteoclasts in the experiment group. Furthermore, Sal B increased vascularity in newly formed bone.

The number of animals used in this study was lower than some previous studies.[7–12] For ethical reasons, the number of animals approved for scientific experiments must be justified and reasonable.[24] In this study, after the statistical power analysis, the number of animals was reduced to the minimum required to achieve a scientific goal.

As previously reported, an expansion spring fixed to the upper incisors was used to expand the premaxilla in rats.[5,6] Mid-palatal separation in rats was reported to be achieved with only 50 to 70 g force.[5] Thus, in this study, all sutures were expanded with 70 g force.

Salvia miltiorrhizae (danshen) is an effective herb that is widely used in traditional medicine for wound and fracture trauma. Cui et al. (2012) reported that Sal B extracted from the Danshen plant inhibited bone resorption with a higher activity of alkaline phosphatase in prednisone-administered rats and could also prevent glucocorticoid-induced bone loss by increasing bone formation in the animals.[22] In another study, Xu et al. (2014) showed that Sal B could increase mesenchymal stem cell osteogenesis.[25] Additionally, He and Shen (2014) observed that Sal B was an effective component in bone healing in rat tibia bone fractures and concluded that Sal B increased the level of alkaline phosphatase, which was active in the healing process.[15] In this study, the results supported the idea that Danshen as a herb and Sal B as a component may have a key role in accelerating bone remodeling.[15]

Researchers have shown that Sal B promoted differentiation of human periodontal ligament cells into osteoblasts or osteogenic differentiation, specifically with the Wnt/β-catenin signaling pathway.[26] In the current study, it was found that osteoblast and osteoclast numbers within the mid-palatal suture increased in rats in which Sal B was administered during RME. The greater number of osteoclasts may have contributed to the quicker bone turnover.

Histopathologic examination showed that Sal B increased the number of capillaries through RME in

Downloaded from http://meridian.allenpress.com/angle-orthodontist/article-pdf/91/2/248/2792805/i0003-3219-91-2-248.pdf by Anadolu University user on 15 December 2022

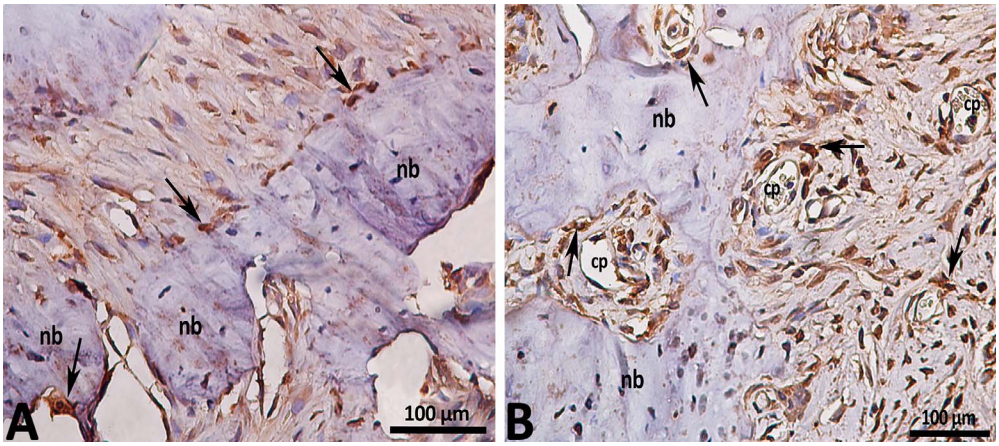

Figure 5. Images of immunohistochemically-stained expansion area sections of the control group (A) and the Sal B group (B). The osteoblast cells (arrow) may be observed on the freshly formed bone area (nb) and capillaries (cp) at the connective tissue. Osteocalcin antibody: Osteoblast marker; Bar: 100 µm.

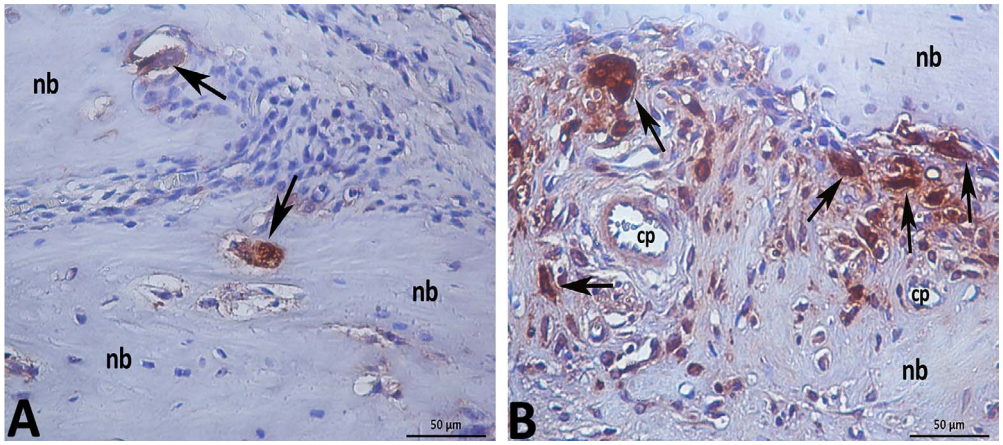

Figure 6. Images of immunohistochemically-analyzed expansion area sections of the control group (A) and the Sal B group (B). The osteoclast multinucleated cells (arrow) may be observed on the newly formed bone (nb) surface and capillaries (cp). Cathepsin K was used as an osteoclast marker; Bar: 100 µm.

Table 1. Descriptive Values and Statistical Comparison Results of Histomorphometric Measurements[a]

Parameters	Groups	N	Mean	SD	SE	Significance (*P* Value)
Newly formed bone area (%)	Sal B	7	52.17	2.26	0.71	.001**
	Control	7	42.38	6.37	1.83	
Number of capillaries	Sal B	7	7.40	1.95	0.62	.003**
	Control	7	4.67	2.06	0.59	
Intensities of inflammatory cells	Sal B	7	1.80	0.79	0.25	.006**
	Control	7	0.83	0.72	0.21	

[a] N indicates sample size; NS, not significant; SD, standard deviation; SE, standard error.
* $P < .05$; ** $P < .01$; *** $P < .001$.

Table 2. Descriptive Values and Statistical Comparison Results of Immunohistochemistry Parameters[a]

Parameters	Groups	N	Mean	SD	SE	Significance (*P* Value)
Number of osteoblasts	Sal B	7	101.80	8.04	3.60	0***
	Control	7	56.50	9.57	3.91	
Number of osteoclasts	Sal B	7	6.20	1.55	0.49	0***
	Control	7	1.17	0.72	0.21	

[a] N indicates sample size; NS, not significant; SD, standard deviation; SE, standard error.
* $P < .05$; ** $P < .01$; *** $P < .001$.

Downloaded from http://meridian.allenpress.com/angle-orthodontist/article-pdf/91/2/248/2792805/i0003-3219-91-2-248.pdf by Anadolu University user on 15 December 2022

rats. The formation of other tissues is closely associated with vascularization (angiogenesis), as well as osteogenesis. It has been reported that Sal B increased hemorrhage and accelerated blood circulation in a study on mice.[27] Lay et al. (2003) also advocated that Sal B promoted angiogenesis.[28] Chang et al. (1997) identified the major osteogenic role of para-vascular cells and concluded that new bone formation required vascular invasion by the blood clot in the mid-palatal suture.[29] According to the findings of the current study, Sal B accelerated angiogenesis with a greater number of capillaries and osteogenesis with a wider area of new bone, higher intensity of inflammation, and greater quantities of osteoblasts and osteoclasts. Consequently, Sal B displayed a positive effect during RME with a greater number of capillaries potentially leading to increased bone formation.

Compared with previous studies that tested plants with high antioxidant capacities such as *Urtica dioica,*[8] *Ginkgo biloba*,[11] and *Hypericum perforatum,*[12] the change in the number of osteoclasts and osteoblasts was similar to the current study. However, these plant extracts are made up of various components and, given the difficulty in obtaining scientific evidence, it was unclear which component has the greatest effect on bone formation. Thus, the balance of the components may change depending on the state of the plants, hence yielding the issue of reproducibility. In a recent study, Lin et al. (2019) showed that Sal B had reasonable chemical stability and showed a positive dose-dependent effect on new bone formation and angiogenesis, further supporting the current results.[23]

The clinical significance and implications of the current findings include the potential to develop new drugs containing Sal B to facilitate new bone formation in the expanded mid-palatal suture during RME treatment. The findings may not only be limited to RME but may also support future potential therapeutic strategies on bone metabolism such as healing after orthognathic surgery.

This study is the first piece of evidence to demonstrate the positive effect of Sal B on new bone formation in the orthopedically expanded suture. However, it will be valuable to conduct more research using different methods before clinical studies are performed.

CONCLUSIONS

- Salvianolic acid B may initiate vascularization and accelerate the formation of new bone after RME in rats. This finding was supported by the evaluation of the following parameters: newly formed bone area, number of capillaries, the intensity of inflammatory cells, number of osteoblasts, and osteoclasts.
- However, it must be noted that this was an animal study; hence, clinical studies are required, particularly on the therapeutic dosage required for Sal B.

ACKNOWLEDGMENTS

This study was financially supported by the Scientific Research Projects Commission (BAP) of Anadolu University (Eskisehir, Turkey) under project number 1701S029. The authors would like to thank Dr Ihsan Savran at the University of Sydney for his contribution to English language editing of the manuscript.

REFERENCES

1. Melsen B. A histological study of the influence of sutural morphology and skeletal maturation on rapid palatal expansion in children. *Trans Eur Orthod Soc*. 1972;499–507.
2. Bishara SE, Staley RN. Maxillary expansion: clinical implications. *Am J Orthod Dentofacial Orthop*. 1987;91(1): 3–14.
3. Chamberland S, Proffit WR. Closer look at the stability of surgically assisted rapid palatal expansion. *J Oral Maxillofac Surg*. 2008;66(9):1895–1900.
4. Saito S, Shimizu N. Stimulatory effects of low-power laser irradiation on bone regeneration in midpalatal suture during expansion in the rat. *Am J Orthod Dentofacial Orthop*. 1997; 111(5):525–532.
5. Deynek GT, Ramoglu SI. Effects of different settings for 940 nm diode laser on expanded suture in rats. *Angle Orthod*. 2019;89(3):446–454.
6. Sawada M, Shimizu N. Stimulation of bone formation in the expanding mid-palatal suture by transforming growth factor-beta 1 in the rat. *Eur J Orthod*. 1996;18(2):169–179.
7. Ozturk F, Babacan H, Gumus C. Effects of zoledronic acid on sutural bone formation: a computed tomography study. *Eur J Orthod*. 2012;34(2):141–146.
8. Irgin C, Corekci B, Ozan F, et al. Does stinging nettle (Urtica dioica) have an effect on bone formation in the expanded inter-premaxillary suture? *Arch Oral Biol*. 2016;69:13–18.
9. Cheng Y, Sun J, Zhou Z, Pan J, Zou S, Chen J. Effects of lactoferrin on bone resorption of midpalatal suture during rapid expansion in rats. *Am J Orthod Dentofacial Orthop*. 2018;154(1):115–127.
10. Altan BA, Kara IM, Nalcaci R, et al. Systemic propolis stimulates new bone formation at the expanded suture: a histomorphometric study. *Angle Orthod*. 2013;83(2):286–291.
11. Kara MI, Altan AB, Sezer U, et al. Effects of Ginkgo biloba on experimental rapid maxillary expansion model: a histomorphometric study. *Oral Surg Oral Med Oral Pathol Oral Radiol*. 2012;114(6):712–718.
12. Halicioglu K, Corekci B, Akkas I, et al. Effect of St John's wort on bone formation in the orthopaedically expanded premaxillary suture in rats: a histological study. *Eur J Orthod*. 2015;37(2):164–169.
13. Chan K, Chui SH, Wong DY, Ha WY, Chan CL, Wong RN. Protective effects of Danshensu from the aqueous extract of Salvia miltiorrhiza (Danshen) against homocysteine-induced endothelial dysfunction. *Life Sci*. 2004;75(26): 3157–3171.

Downloaded from http://meridian.allenpress.com/angle-orthodontist/article-pdf/91/2/248/2792805/i0003-3219-91-2-248.pdf by Anadolu University user on 15 December 2022

14. Hu P, Luo GA, Zhao Z, Jiang ZH. Quality assessment of radix salviae miltiorrhizae. *Chem Pharm Bull*. 2005;53(5): 481–486.
15. He X, Shen Q. Salvianolic acid B promotes bone formation by increasing activity of alkaline phosphatase in a rat tibia fracture model: a pilot study. *BMC Compl Altern Med*. 2014; 14:493.
16. Li YG, Song L, Liu M, Hu ZB, Wang ZT. Advancement in analysis of Salviae miltiorrhizae Radix et Rhizoma (Danshen). *J Chromatogr. A*. 2009;1216(11):1941–1953.
17. Ren Y, Tao S, Zheng S, et al. Salvianolic acid B improves vascular endothelial function in diabetic rats with blood glucose fluctuations via suppression of endothelial cell apoptosis. *Eur J Pharmacol*. 2016;791:308–315.
18. Lee YW, Kim DH, Jeon SJ, et al. Neuroprotective effects of salvianolic acid B on an Abeta25-35 peptide-induced mouse model of Alzheimer's disease. *Eur J Pharmacol*. 2013; 704(1-3):70–77.
19. Tang Q, Zhong H, Xie F, Xie J, Chen H, Yao G. Expression of miR-106b-25 induced by salvianolic acid B inhibits epithelial-to-mesenchymal transition in HK-2 cells. *Eur J Pharmacol*. 2014;741:97–103.
20. Zhang DF, Zhang J, Li R. Salvianolic acid B attenuates lung inflammation induced by cigarette smoke in mice. *Eur J Pharmacol*. 2015;761:174–179.
21. Jing Z, Fei W, Zhou J, et al. Salvianolic acid B, a novel autophagy inducer, exerts antitumor activity as a single agent in colorectal cancer cells. *Oncotarget*. 2016;7(38): 61509–61519.
22. Cui L, Li T, Liu Y, et al. Salvianolic acid B prevents bone loss in prednisone-treated rats through stimulation of osteogenesis and bone marrow angiogenesis. *PloS one*. 2012;7(4): e34647.
23. Lin S, Cui L, Chen G, et al. PLGA/beta-TCP composite scaffold incorporating salvianolic acid B promotes bone fusion by angiogenesis and osteogenesis in a rat spinal fusion model. *Biomaterials*. 2019;196:109–121.
24. Fitts DA. Ethics and animal numbers: informal analyses, uncertain sample sizes, inefficient replications, and type I errors. *J Am Assoc Lab Anim Sci*. 2011;50(4):445–453.
25. Xu D, Xu L, Zhou C, et al. Salvianolic acid B promotes osteogenesis of human mesenchymal stem cells through activating ERK signaling pathway. *Int J Biochem Cell B*. 2014;51:1–9.
26. Bian Y, Xiang J. Salvianolic acid B promotes the osteogenic differentiation of human periodontal ligament cells through Wnt/beta-catenin signaling pathway. *Arch Oral Biol*. 2020; 113:104693.
27. Pan C, Lou L, Huo Y, et al. Salvianolic acid B and tanshinone IIA attenuate myocardial ischemia injury in mice by NO production through multiple pathways. *Ther Adv in Cardiac Dis*. 2011;5(2):99–111.
28. Lay IS, Chiu JH, Shiao MS, Lui WY, Wu CW. Crude extract of Salvia miltiorrhiza and salvianolic acid B enhance in vitro angiogenesis in murine SVR endothelial cell line. *Planta medica*. 2003;69(1):26–-32.
29. Chang HN, Garetto LP, Potter RH, Katona TR, Lee CH, Roberts WE. Angiogenesis and osteogenesis in an orthopedically expanded suture. *Am J Orthod Dentofacial Orthop*. 1997;111(4):382–390.

Downloaded from http://meridian.allenpress.com/angle-orthodontist/article-pdf/91/2/248/2792805/i0003-3219-91-2-248.pdf by Anadolu University user on 15 December 2022